Journal of Pediatric Urology (2013) 9, 763–768

Journal of Pediatric urology

# Glans amputation during routine neonatal circumcision: Mechanism of injury and strategy for prevention

Joao L. Pippi Salle [a,*], Lisieux E. Jesus [a], Armando J. Lorenzo [a], Rodrigo L.P. Romão [a], Victor H. Figueroa [a], Darius J. Bägli [a], Edward Reda [b], Martin A. Koyle [a], Walid A. Farhat [a]

[a] *Division of Urology, The Hospital for Sick Children and University of Toronto, 555 University Ave. Rm M299, Toronto, ON M5G 1X8, Canada*
[b] *Division of Pediatric Urology, Steven and Alexandra Cohen Children's Medical Center of New York, New Hyde Park, NY, USA*

Received 30 May 2012; accepted 13 September 2012
Available online 5 November 2012

**KEYWORDS**
Circumcision;
Mogen clamp;
Amputation;
Glans;
Penile reconstruction;
Complication

**Abstract** *Objective:* Glans injury during circumcision is an uncommon yet potentially devastating complication. Its mechanism remains poorly understood. Herein we critically evaluate a case series and, based on common characteristics, hypothesize the mechanism of injury as well as means to prevent it.
*Methods:* Retrospective review of circumcision-related glans amputation cases referred for evaluation and management, focusing on detection of common history and presentation patterns in order to evaluate possible underlying mechanisms.
*Results:* A neonatal elective circumcision was conducted using a Mogen clamp and an oblique injury to the ventro-lateral aspect of the glans was noted in 6 cases referred over a 5-year period, suggesting a similar trauma pattern. The urethra was consistently involved. The amputated segments were reattached as free composite grafts in 2/6 cases. Three patients underwent delayed glansplasty months after the trauma in an attempt to restore natural symmetry and cosmesis. In one case a buccal mucosa graft was employed to rebuild the ventral coronal sulcus.
*Conclusions:* Trauma pattern suggests that the ventral glans is at high risk for injury by traction on incompletely released ventral preputial adhesions with subsequent glans entrapment.

* Corresponding author. Tel.: +1 416 813 6580 (office); fax: +1 416 813 6461.
*E-mail addresses:* pippi.salle@sickkids.ca (J.L. Pippi Salle), lisieuxeyerdejesus@gmail.com (L.E. Jesus), armando.lorenzo@sickkids.ca (A.J. Lorenzo), rodrigo.romao@sickkids.ca (R.L.P. Romão), victor.figueroa@sickkids.ca (V.H. Figueroa), darius.bagli@sickkids.ca (D.J. Bägli), edreda@optonline.net (E. Reda), martin.koyle@sickkids.ca (M.A. Koyle), walid.farhat@sickkids.ca (W.A. Farhat).


http://dx.doi.org/10.1016/j.jpurol.2012.09.012

Practitioners performing neonatal circumcisions, particularly with a Mogen clamp, should exercise adequate release of ventral adhesions to prevent this complication.


## Introduction

Circumcision is considered to be one of the most commonly performed surgical procedure in the world, frequently related to timeless rituals with important religious connotations, and distinctly being often performed for non-therapeutic reasons [1]. It is estimated that a quarter of the males worldwide are circumcised. In some communities almost all boys undergo ritual circumcision as newborns. Depending on cultural and social backgrounds the procedure may be performed by a myriad of health care providers with different backgrounds, as well as non-specialized physicians, non-medical health personnel or lay people, giving margin to different frequencies and types of complications [1,2]. In stark contrast with other medical interventions, even in jurisdictions with tight control over surgical practice, the ritual circumcision by practitioners with different levels of training and specialization is tolerated and accepted by legislation and the public. Not surprisingly, the reported incidence of circumcision-related complications varies in the literature, from 0.2% (in-hospital circumcisions, mostly conducted by trained health care practitioners) to >20% (out of hospital procedures, often performed by lay people) [2].

There are various techniques for circumcision. In particular, clamp techniques are popular as they can be performed quickly and inexpensively. They can also be easily taught and learned, without need for refined surgical expertise. Although most patients do well regardless of the selected technique, bleeding and infection remain relatively common complications that generate anxiety among family members and physicians. Fortunately these are easily addressed by compression, surgical exploration or medical treatment, with few long-term consequences. In contrast, glans injury during circumcision is an uncommon and possibly underreported yet devastating complication. Partial or complete glans amputation, caused by inadvertent transection during the foreskin-removing process, is particularly relevant due to its associated morbidity and long-term consequences. Unfortunately, prevention measures have been scarce and difficult to come by considering that its exact pathophysiology remains poorly understood.

In order to better understand the factors related to this iatrogenic injury, herein we report a retrospective series of glans amputation cases that were managed by (or in consultation with) a senior pediatric urologist, reflecting on possible mechanisms that may predispose to glans injury during this procedure.

## Material and methods

A retrospective analysis of all cases of traumatic glans amputations complicating circumcisions referred for review or treatment by the senior author (JLPS) *in a 10-year period* was conducted. Data were collected on technical operative details (including type of surgical procedure and instrumentation employed), obtained by history on admission or by review of the operative notes sent with the referrals. Narratives, histories and physical exam were reviewed to determine common factors detected in affected children. Management strategies and long-term outcomes are presented (when available).

## Results

A total of 6 patients were identified, who underwent circumcision between 8 and 12 days of age. All infants underwent circumcision using a Mogen clamp, under local anesthesia. Non-surgical medical consultants (pediatricians or general practitioners) performed the procedure in all cases. All patients were hemodynamically stable on admission. None required blood transfusion, although post-circumcision anemia was reported in 5 of the 6 patients. In all cases partial glans amputation occurred in an oblique fashion, leaving more glanular tissue on the superior/dorsal aspect.

Two patients were seen soon after the procedure with the portion of amputated glans properly stored in normal saline, allowing for timely reimplantation (Fig. 1a–d).

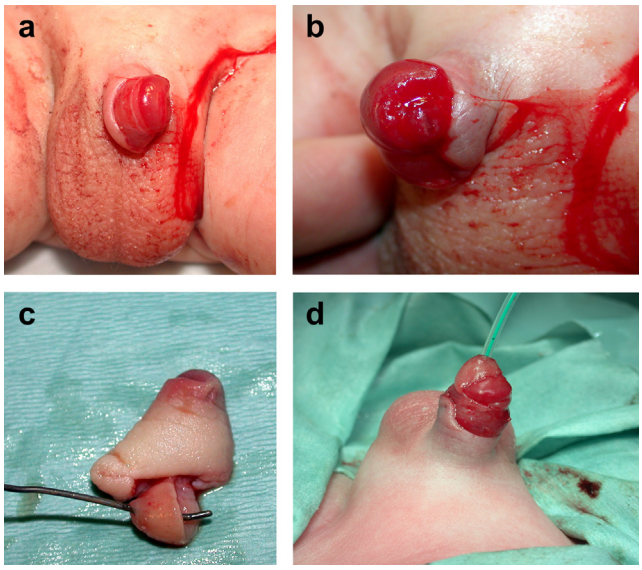


**Figure 1** a and b — Appearance of penis following glans amputation after Mogen clamp circumcision. Note the oblique orientation of the injury, involving the distal urethra. c — Amputated distal penile portion consisting of prepuce and part of the glans. Preputial adhesions improperly released are clearly seen in the ventral aspect, around the frenulum. d — Early appearance of the reimplanted segment of amputated glans, showing good color and grossly viable.

Examination of one of the specimens demonstrated residual adhesions between the remaining glanular tissue (*in situ*) and the inner preputial mucosa. Late follow-up of these cases (3 and 5 years respectively) demonstrated a viable reimplanted glans segment with moderate degree of hypoplasia (Fig. 2a). Due to age constraints it has not been possible to evaluate if the reimplanted glans tissue recovered innervation and thus, sensitivity.

In the remaining 4 patients presentation was delayed: detection took place after removal of the compressive surgical dressing in 2 and after several months in the other 2, when the typical oblique amputation scar with a round shaped urethral meatus was clearly appreciated. Glansplasty was performed in 3 of these patients, using split skin grafts ($n = 2$) and a labial mucosa graft to reconstruct the glanular groove ($n = 1$; Fig. 3). The urethral meatus was always involved. In 2 cases (where reimplantation of the amputated segment was conducted) reconstruction included a distal urethro-urethrostomy. Three patients underwent meatoplasty in order to achieve a normal slit-like shape. Of these one subsequently developed stenosis, and was managed with dilatations. One patient did not undergo reconstruction and remains with mild glanular deformity and slight meatal deformity.

**Figure 3** Status post glansplasty with reconstruction of the glanular groove using a narrow strip of lower lip buccal mucosa.

## Discussion

Circumcision related complications are among the most common aetiologies of penile trauma in children, being reported in 0.1—35% of cases [2]. Important risk factors include the employed surgical technique, the patient's age, as well as the experience of the person performing the procedure [3,4]. Neonatal circumcisions are usually conducted following one of three basic surgical patterns: Guillotine transection of the foreskin after crushing or entrapping the tissue planned for removal (most commonly with the Mogen clamp), foreskin resection following mechanical strangulation with glans protection using a cap-shaped guard (as seen with the PlastiBell circumcision device, Hollister Inc., Libertyville, IL; or the Gomco clamp), and "free-hand" procedures (which usually follows the double-circular incision or sleeve resection technique employed during most circumcisions performed in older patients in the operating room). Each type has its proponents, likely favored based on comfort with the particular technique, training and cumulative experience with good or bad results. As expected, the complication profile varies among them and can be particular to a singular device.

**Figure 2** Long-term appearance of the reimplanted segment, which underwent progressive hypotrophy and effacement of the glanular groove.

The Mogen clamp is one of the most popular device, favored by many based on the belief that it is easy and quick to perform while producing good outcomes with few complications [5]. According to Strimling [5], the use of Mogen clamp has important particular advantages: There is no need to size the instrument to the phallus, under experienced hands it is one of the quickest to complete and the instrument allows full visualization of exactly how much prepuce to remove. The main drawback is that the glans is not directly visualized during placement of the clamp and cutting the skin, thus any inclusion of glanular tissue can only be suspected by palpation or (after the fact) once the injury has occurred. In stark contrast, the PlastiBell and Gomco differ from the Mogen clamp, as these devices incorporate a glans protective mechanism that minimizes its inclusion and injury during the circumcision [1,6].

The most commonly reported procedure-related complications are infection (especially in developing countries and out-of-hospital environments) and bleeding. Treatment for both is fairly straightforward and rarely leads to long-term consequences. Hemorrhage is relatively easy to control with compressive dressings or cauterization, with or without sutures. The main caveat in these cases is the possibility of a bleeding disorder, which can lead to serious bleeding if the coagulation abnormality is not addressed. In rare circumstances hypovolemic shock and even deaths have been reported, raising concerns and heightening efforts to minimize the chances of post-operative bleeding [7].

In the present case series we report on 6 ("*consecutive*" *removed* ) cases of glans amputations during neonatal circumcision following use of the Mogen clamp. Interestingly, all lesions followed an oblique pattern and involved the distal urethra, suggesting a common mechanism of injury. Based on the evaluation of these patients' injuries, we suggest that the incurred glans trauma is likely due to incomplete release of the physiological balano-preputial adhesions around the frenulum, which would produce traction of the ventral aspect of the glans when the foreskin is pulled in order to secure the clamp. Therefore we propose that glans amputations during circumcision may be prevented by careful and complete release of the inner preputial mucosa from the glans prior to the placement of the clamp (Fig. 4). The reasons behind incomplete release of peri-frenular physiological attachments are unknown. We hypothesize that fear of inadvertent injury to the frenular artery, which is the most common cause of serious bleeding post circumcision, plays a role. Nevertheless, health care professionals performing circumcisions with this device may decrease their complications by following this rather simple recommendation. Indeed, in some settings the financial implications related to this complication can be rather substantial and multi-million dollar lawsuits related to this matter have taken place.

The use of entrapment clamps for pediatric circumcision is supported by authors who attest to its safety [6,8,9]. Although complications are commonly reported (some in disproportionate rates when compared to other techniques), the popularity of these devices for circumcision has to be taken into account. Furthermore, the incidence of complications is likely related to the expertise of the operator, irrespective of the environment where the procedure is conducted [9]. In a retrospective review of 270 consecutive circumcisions performed by nurses (60%), doctors (35%) and by traditional circumcisors (5%) in infants $<$ 1 month of age, Okeke et al. reported 20% of complications and an alarming incidence of glans amputations (1.5%) [2]. According to Sherman et al. [10] glans amputation is uncommonly seen, but may represent between 3.1 and 14.3% of the complications after circumcision [1,11—13], depending on the authors' criteria to define "relevant" complications. In a recent systematic review of pediatric circumcision complications, despite the authors' attempt at stratifying complications by severity, the incidence of glans amputation was not amenable to objective calculation [14]. In addition to our previously reported case [15] we found several case reports of glans amputation related to the usage of clamps [5,8,9,16]. In a literature review we found 31 reported cases of glans injury during circumcision (Table 1). Interestingly, as a common denominator, whenever the injury was described in some detail the patterns appear to follow a ventral oblique direction similar to our cases.

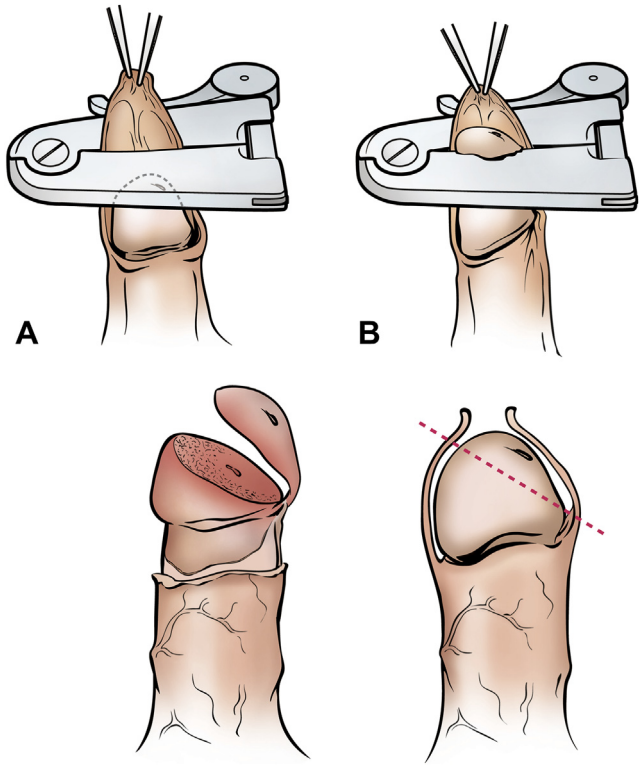


**Figure 4** Diagram illustrating the proposed mechanism of injury to the glans during clamp-assisted circumcision. A: Adequate release of adhesions. The glans slides down, below the clamp. B: Inadequate release of adhesions: the tip of the glans is pulled up and trapped by the clamp.

As mentioned, laceration of the frenular artery may occur during release of the ventral preputial adhesions, reason why this maneuver is avoided by some. Without proper release, the attached ventral foreskin or a high frenular insertion can lead to glanular traction and inclusion within the cutting edges of the clamp, leading to distal amputation in an oblique fashion (Fig. 3). This hypothesis is supported by Sherman and others, who have stated: "If the ventral foreskin is advanced too far distally, it may pull up on the frenulum, which in turn will bring the urethral meatus and ventral glans forward as well. When this happens, a portion of the glans may be excised with the ventral penile and frenular skin attached to it. This is the proposed mechanism of injury for the majority of our patients" [10,13,17]. The importance of releasing these adhesions dates to ancient times, including Old Testament citations. Rabi Moshe Ben Mimon (Maimonides), one of the most famous ancient doctor and philosopher who lived in Spain and Egypt, explained that the Mohel should perform *PRIA* (release of the balano-preputial adhesions) with his finger nail until the glans is visible before cutting the prepuce. Today most Jewish ritual practitioners use a probe to conduct this maneuver during ritual circumcisions.

Treatment following a glans injury depends on the time interval following the trauma event, severity of bleeding and availability of the amputated segment (which, under ideal circumstances, should be properly preserved). If the glans tissue is completely detached it is advisable to wrap it in a moist piece of gauze and place it into a plastic bag immersed in cold water. The tissue must not be placed directly on ice to avoid freezing injury. Whenever possible the glans segment should be immediately reimplanted over the raw transection edges, after local debridement as necessary. Microsurgical vascular techniques are not feasible even when technical expertise is available, because of the small caliber of the crushed vessels [18]. The glans graft should be meticulously sutured to each of

**Table 1** Previously published series on circumcision complications including glans amputation.

| Author | Cases | Mechanism | Orientation | Urethra | Reimplantation | Treatment | Age | Complication |
|---|---|---|---|---|---|---|---|---|
| Ceylan, K [1] | 4 | Not detailed | Not given | 4 | No | Buccal graft | Not reported | — |
| Hanash, K [20] | 1 | Guillotine | Complete | 1 | No | Skin graft | 2 y | — |
| Ozkan, S [16] | 1 | Guillotine | Complete, oblique | 1 | Yes | Reimplantation with vascular and urethral anastomosis | 10 y | Glans necrosis. |
| Okeke, L [2] | 2 | Not reported | No details | Unknown | Unknown | Not reported | Not reported | Not reported. |
| Cook, A [15] | 1 | Guillotine | Oblique | 1 | Yes | Reimplantation | 7 days | No groove: buccal graft plasty. |
| El-Bahanasawy [3] | 6 | Guillotine (bone cutter) | Oblique | 6 | No details | Meatoplasty | No details | No details. |
| Gluckman, G [9] | 1 | Guillotine (Sheldon clamp) | Oblique | 1 | Yes | Reimplantation | Newborn | Glans hypoplasia. |
| Sherman, J [10] | 7 | Guillotine in 6, free hand in 1 | Oblique | 6 | 6 cases | Reimplantation | 6: 8 days old; 1 case 1 month | Urethral fistula (1 case). |
| Strimling, J [5] | 1 | Guillotine (Mogen clamp) | Oblique | 1 | 1 | Reimplantation | Newborn | — |
| Baskin, L [17] | 3 | Possibly Guillotine | Oblique | 3 | No | Meatoplasty and glanuloplasty | Possibly newborns | — |
| Patel, H [21] | 3 | Guillotine (Mogen clamp) | No details | 1 | No | Epinephrine for bleeding, delayed meatal advancement glansplaty [1] | Newborns | "Flattened appearance". |
| Conkusfirat, O [18] | 1 | Unknown | Whole glans | 1 | Yes | Reimplantation. | 8 y | Necrosis. |

the anatomical plans (spongiosum and urethra). The urethra needs to be stented for at least a week, as post-operative meatal stenosis is common [16,17,19]. Successful glans reimplantation has been reported up to 8 h following injury [16]. When the amputated glans segment is not available or suitable for reconstruction, the defect can grafted with skin or buccal mucosa [1,19], with the urethra similarly stented to prevent stenosis. When possible, we prefer to defer the skin grafting for several months to allow the injury to demarcate and heal completely. In our experience many patients benefit from secondary procedures to improve cosmesis or address urethral complications. In addition, progressive glans graft hypotrophy and consequent deformity occur in some cases. Dysmorphic glans, urethral deviation due to scarring, meatal stenosis and obliteration of the balano-preputial groove are commonly seen (Fig. 2). Re-intervention may be required, including glansplasties, meatoplasties, urethral mobilizations, neo-urethroplasties and the use of buccal mucosa grafts to reconstruct the sulcus [15].

There are important limitations of this work that must be acknowledged. By virtue of its retrospective nature and with a small number of cases it is difficult to confidently establish a causal association with the particular use of the Mogen clamp. Furthermore, the proposed mechanism of trauma follows a hypothesis based on limited observations *and taking down the penile adhesions may not prevent all cases of glans amputation*. Nevertheless, we propose there is value in this report as it highlights an easy step that should be conducted during this controversial surgical procedure, irrespective of the technique followed.

## Conclusion

Glans amputation during neonatal circumcision is a potentially devastating complication that appears to be particularly associated with the use of the Mogen clamp. We propose that it can be prevented by careful preparation of the foreskin with complete lysis of ventral preputial adhesions prior to the placement of the clamp in order to avoid traction and inadvertent entrapment.

## Conflicts of interest

None of the authors have any conflicts of interest to declare.

## Funding source

This study did not receive any sort of specific funding.

## Ethics approval

The study received approval by the Research Ethics Board.

## References

[1] Ceylan K, Burhan K, Yilmaz Y, Can S, Kuş A, Mustafa G. Severe complications of circumcision: an analysis of 48 cases. J Pediatr Urol 2007 Feb.;3(1):32—5.
[2] Okeke LI, Asinobi AA, Ikuerowo OS. Epidemiology of complications of male circumcision in Ibadan, Nigeria. BMC Urol 2006;6:21.
[3] El-Bahnasawy MS, El-Sherbiny MT. Paediatric penile trauma. BJU Int 2002 Jul.;90(1):92—6.
[4] Harrison NW, Eshleman JL, Ngugi PM. Ethical issues in the developing world. Br J Urol 1995 Nov.;76(Suppl. 2):93—6.
[5] Strimling BS. Partial amputation of glans penis during Mogen clamp circumcision. Pediatrics 1996 Jun.;97(6 Pt 1): 906—7.
[6] Kaweblum YA, Press S, Kogan L, Levine M, Kaweblum M. Circumcision using the Mogen clamp. Clin Pediatr (Phila) 1984 Dec.;23(12):679—82.
[7] Sasmaz I, Antmen B, Leblebisatan G, Sahin Karagün B, Kilinç Y, Tuncer R. Circumcision and complications in patients with haemophilia in southern part of Turkey: Çukurova experience. Haemophilia 2012 May;18(3):426—30.
[8] Peleg D, Steiner A. The Gomco circumcision: common problems and solutions. Am Fam Physician 15 Sep 1998;58(4):891—8.
[9] Gluckman GR, Stoller ML, Jacobs MM, Kogan BA. Newborn penile glans amputation during circumcision and successful reattachment. J Urol 1995 Mar.;153(3 Pt 1):778—9.
[10] Sherman J, Borer JG, Horowitz M, Glassberg KI. Circumcision: successful glanular reconstruction and survival following traumatic amputation. J Urol 1996 Aug.;156(2 Pt 2):842—4.
[11] Dieth AG, Moh-Ello N, Fiogbe M, Yao KJB, Tembely S, Bandre E, et al. Accidents of circumcision in children in Abidjan, Côte d'Ivoire. Bull Soc Pathol Exot 2008 Oct.;101(4):314—5.
[12] Sylla C, Diao B, Diallo AB, Fall PA, Sankale AA, Ba M. Complications of circumcision. Report of 63 cases. Prog Urol 2003 Apr.;13(2):266—72.
[13] Magoha GA. Circumcision in various Nigerian and Kenyan hospitals. East Afr Med J 1999 Oct.;76(10):583—6.
[14] Weiss HA, Larke N, Halperin D, Schenker I. Complications of circumcision in male neonates, infants and children: a systematic review. BMC Urol 2010;10:2.
[15] Cook A, Khoury AE, Bägli DJ, Farhat WA, Pippi Salle JL. Use of buccal mucosa to simulate the coronal sulcus after traumatic penile amputation. Urology 2005 Nov.;66(5):1109.
[16] Ozkan S, Gürpinar T. A serious circumcision complication: penile shaft amputation and a new reattachment technique with a successful outcome. J Urol 1997 Nov.;158(5):1946—7.
[17] Baskin LS, Canning DA, Snyder HM, Duckett JW. Surgical repair of urethral circumcision injuries. J Urol 1997 Dec.;158(6): 2269—71.
[18] Coŝkunfirat OK, Sayilkan S, Velidedeoglu H. Glans and penile skin amputation as a complication of circumcision. Ann Plast Surg 1999 Oct.;43(4):457.
[19] Palminteri E, Berdondini E, Lazzeri M, Mirri F, Barbagli G. Resurfacing and reconstruction of the glans penis. Eur Urol 2007 Sep.;52(3):893—8.
[20] Hanash KA. Plastic reconstruction of partially amputated penis at circumcision. Urology 1981 Sep.;18(3):291—3.
[21] Patel HI, Moriarty KP, Brisson PA, Feins NR. Genitourinary injuries in the newborn. J Pediatr Surg 2001 Jan.;36(1):235—9.