

Letters

Follow-Up Information About the Four Pregnant Patients With Coronavirus Disease (COVID-19) Pneumonia Who Were Still in the Hospital at the End of Our Study

We appreciate the interest in our *AJR* article “Pregnancy and Perinatal Outcomes of Women With Coronavirus Disease (COVID-19) Pneumonia: A Preliminary Analysis” [1], which

was published online on March 18, 2020. In that study [1], we reported the clinical data and CT manifestations of 15 pregnant women with COVID-19 pneumonia. At the end of the study period, four of the 15 women were still pregnant and had not been discharged from the hospital. The purpose of this letter is to describe the short-term follow-up of these four patients.

The COVID-19 outbreak is rapidly increasing in the numbers of cases, deaths, and countries affected. The number of deaths caused by severe acute respiratory syndrome coronavirus 2 (SARS-CoV-2), the virus that causes COVID-19, has exceeded the number of deaths caused by the severe acute respiratory syndrome coronavirus (SARS-CoV) during the 2002–2003 severe acute respiratory syndrome (SARS) outbreak. As of this writing in mid April 2020, limited data are available on pregnant women with COVID-19.

We reviewed the clinical data and CT examinations of the four patients; they were identified in our study [1] as patients 12–15. By March 30, 2020, all four patients had been discharged from the hospital, and all were still pregnant. All patients had negative results on two consecutive SARS-CoV-2 quantitative reverse transcription–polymerase chain reaction (RT-PCR) tests that were performed at least 24 hours apart. The timeline of hospitalization, CT examinations, and RT-PCR testing for patients 12–15 is shown in Figure 1. After the four patients had received treatment and before they were discharged from the hospital, their lymphocyte count, C-reactive protein value, and body temperature had returned to normal values, and cough and other symptoms had disappeared. Neither preterm delivery nor spontaneous abortion occurred in these four patients. One patient, patient 12, underwent low-dose chest CT follow-up. Chest CT showed significant absorption of the pulmonary lesions, and the semiquantitative CT score decreased from 10 to 4 (Fig. 2).

SARS-CoV and Middle East respiratory syndrome coronavirus (MERS-CoV) were reported to be associated with poor obstetric outcomes in infected pregnant women, including serious complications and death [2, 3]. However, in our study, all 15 pregnant women with confirmed COVID-19 pneumonia and up to 2 months of observation since symptom onset did not experience severe symptoms and did not experience acute respiratory distress syndrome. The four patients who were still in the hospital at the end of the study period achieved a good recovery. When they were being discharged from the hospital, the patients were advised to con-

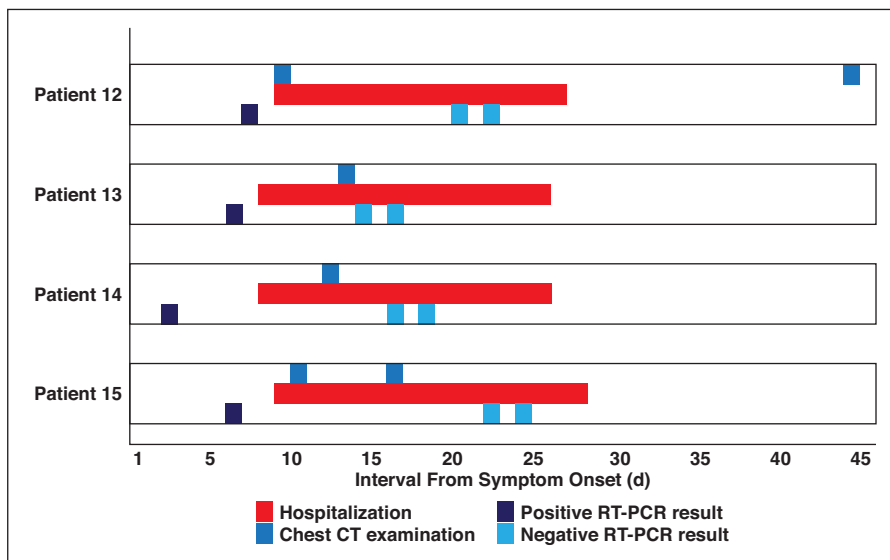


Fig. 1—Chart shows clinical course in four pregnant women (patients 12–15 in Liu et al. [1]) with coronavirus disease (COVID-19) pneumonia. RT-PCR = reverse transcription–polymerase chain reaction.

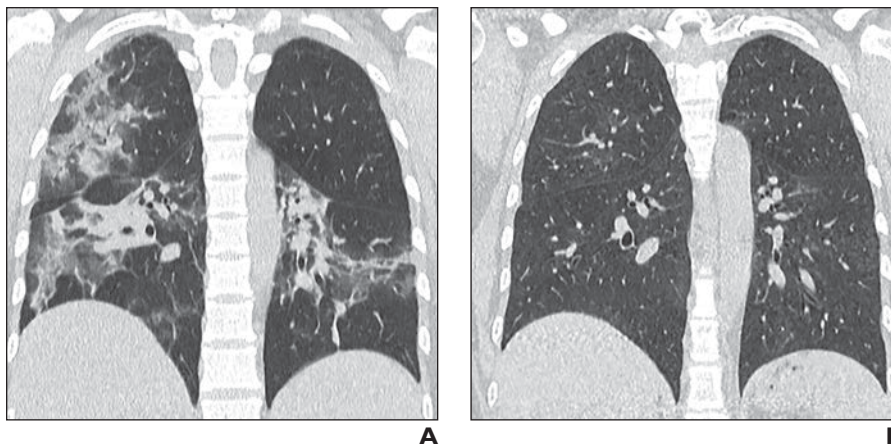


Fig. 2—35-year-old pregnant woman (patient 12 in Liu et al. [1]) who presented with mild coronavirus disease (COVID-19) pneumonia when pregnant and underwent two CT examinations before delivery. **A**, Coronal chest CT image obtained during peak stage (stage 3) shows multiple ground-glass opacities (GGOs) with partial consolidation in both lungs. **B**, Follow-up coronal chest CT image obtained 34 days after **A** during absorption stage (stage 4) shows GGOs and consolidation have been mostly absorbed.

Letters

tinue to get adequate rest, hydration, and nutritional support and ensure adequate water and electrolyte balance. They were instructed to monitor their vital signs closely. As of April 8, 2020, no maternal deaths have been reported in pregnant women with SARS-CoV-2 infection, to our knowledge, and the clinical findings of pregnant women have been similar to those in nonpregnant adults.

In conclusion, our observations in our article [1] and this letter provide a basis for guidelines on monitoring and treatment of pregnant women with confirmed COVID-19 pneumonia. Our findings indicate that treatment of pregnant women with antiviral drugs, which are associated with potential

risks to the fetus, may not be a prerequisite for recovery from COVID-19 pneumonia.

Lin Li
Dehan Liu
Lian Yang
*Union Hospital
Tongji Medical College
Huazhong University of Science and
Technology
Hubei Province Key Laboratory of
Molecular Imaging
Wuhan, China
yanglian@hust.edu.cn*

doi.org/10.2214/AJR.20.23247

WEB—This is a web exclusive article.

References

1. Liu D, Li L, Wu X, et al. Pregnancy and perinatal outcomes of women with coronavirus disease (COVID-19) pneumonia: a preliminary analysis. *AJR* 2020; 215:126–132
2. Wong SF, Chow KM, de Swiet M. Severe acute respiratory syndrome and pregnancy. *BJOG* 2003; 110:641–642
3. Assiri A, Abedi GR, Al Masri M, Bin Saeed A, Gerber SI, Watson JT. Middle East respiratory syndrome coronavirus infection during pregnancy: a report of 5 cases from Saudi Arabia. *Clin Infect Dis* 2016; 63:951–953