

Case Report

Fetal Transient Skin Edema in Two Pregnant Women With Coronavirus Disease 2019 (COVID-19)

*Pablo Garcia-Manau, MD,
Itziar Garcia-Ruiz, MD,
Carlota Rodó, MD, PhD,
Elena Sulleiro, MD, PhD,
Nerea Maiç, MD, PhD,
Marina Catalan, MD,
Nuria Fernández-Hidalgo, MD, PhD,
Joan Balcells, MD, PhD,
Andrés Antón, MD, PhD,
Elena Carreras, MD, PhD,
and Anna Suy, MD, PhD*

BACKGROUND: The risk of vertical transmission of severe acute respiratory syndrome coronavirus 2 (SARS-CoV-2) infection remains unknown. Positive reverse-transcription polymerase chain reaction (RT-PCR) test results for SARS-CoV-2 infection in neonates and placental tissue have been reported, and immuno-

globulin M antibodies have been detected in neonates born to mothers with infection.

CASES: The first case is a woman at 22 3/7 weeks of gestation with coronavirus disease 2019 (COVID-19) who was admitted to the intensive care unit. In the second case, the patient remained at home with mild symptoms, starting at 20 weeks of gestation. In both cases, fetal skin edema was observed on ultrasound examination while maternal SARS-COV-2 RT-PCR test results were positive and resolved when maternal SARS-COV-2 RT-PCR test results became negative. The RT-PCR test result for SARS-CoV-2 in amniotic fluid was negative in both cases. The two pregnancies are ongoing and uneventful.

CONCLUSION: Transient fetal skin edema noted in these two patients with COVID-19 in the second trimester may represent results of fetal infection or altered fetal physiology due to maternal disease or may be unrelated to the maternal illness.

(*Obstet Gynecol* 2020;00:1–5)

DOI: 10.1097/AOG.0000000000004059

Coronavirus disease 2019 (COVID-19) is a highly infectious disease caused by severe acute respiratory syndrome coronavirus 2 (SARS-CoV-2). Spain reported its first case on January 31, 2020, and more than 241,000 confirmed cases and 27,100 deaths have been reported.¹

Some maternal infections during pregnancy are associated with poor perinatal outcomes and fetal anomalies. In infections such as cytomegalovirus or Zika virus, gestational age at the time of maternal infection plays a role in the risk of both intrauterine infection and severe sequelae.^{2,3} In SARS-CoV-2 infection, there is a paucity of reports of pregnancy outcomes with infection before the third trimester.

The risk of maternal–fetal transmission of SARS-CoV-2 infection remains controversial. Severe acute respiratory syndrome coronavirus 2 has been detected in placental swabs or biopsies in five cases, but not in amniotic fluid.^{4–7} However, it is unknown whether the virus, the immune response it causes, or the gestational age at which the infection occurs may have consequences for the fetus.⁸

From the Maternal Fetal Medicine Unit, Department of Obstetrics, the Microbiology Department, the Pediatric Critical Care Department, and the Department of Infectious Diseases, Vall d'Hebron Barcelona Hospital Campus, Universitat Autònoma de Barcelona, Barcelona, and the Red Española de Investigación en Patología Infecciosa (REIPI), Instituto de Salud Carlos III, Madrid, Spain.

Funding was provided for the Gesta-COVID19 Study by Instituto de Salud Carlos III (ISCIII) (PR(AMI)181/2020) (ISCIII's reference: COV20/00188).

The authors thank all the members of the Gesta-COVID19 Collaboration Group for their help in data collection for the Gesta-COVID19 Study, and Erika Bokor for the English language correction of the manuscript.

Each author has confirmed compliance with the journal's requirements for authorship.

Corresponding author: Carlota Rodó, MD, PhD, Department of Obstetrics, Vall d'Hebron Barcelona Hospital Campus, Passeig Vall d'Hebron, Barcelona, Spain; email: crodo@vhebron.net.

Financial Disclosure

The authors did not report any potential conflicts of interest.

© The Author(s). Published by Wolters Kluwer Health, Inc. This is an open-access article distributed under the terms of the Creative Commons Attribution-Non Commercial-No Derivatives License 4.0 (CCBY-NC-ND), where it is permissible to download and share the work provided it is properly cited. The work cannot be changed in any way or used commercially without permission from the journal.

ISSN: 0029-7844/20

Teaching Point

1. Maternal coronavirus disease 2019 (COVID-19) might have an effect on the fetus during pregnancy.

Herein, we present two cases of unexplained fetal skin edema in two pregnant women diagnosed with COVID-19 during the second trimester of pregnancy.

CASE 1

A 50-year-old primigravid woman at 22 6/7 weeks of gestation presented to the emergency department at Vall d'Hebron University Hospital (Barcelona, Spain) with a 7-day history of dry cough and fever. She was living with her mother, who had tested positive for SARS-CoV-2 infection on reverse-transcription polymerase chain reaction (RT-PCR) testing. The patient was a former smoker, had no relevant medical history, and was receiving 150 mg of acetylsalicylic acid owing to a high risk of early-onset preeclampsia. Her gestation was conceived by in vitro fertilization with egg donation and had had an uneventful course. No genetic tests had been performed during the pregnancy. Physical examination revealed a body mass index (BMI, calculated as weight in kilograms divided by height in meters squared) of 25.4, blood pressure 125/64 mm Hg, temperature 37°C, and respiratory rate of 30 breaths per minute, with a hemoglobin saturation by pulse oximetry of 93% on room air. Blood tests performed at admission showed lymphopenia and interleukin-6 (IL-6) and D-dimer levels above the normal range (Table 1).

A chest radiograph showed conspicuous bilateral ground glass opacities, and the patient tested positive for SARS-CoV-2 infection on RT-PCR testing of oropharyngeal and nasopharyngeal swabs (Allplex 2019-nCoV assay). A COVID-19 bilateral pneumonia was diagnosed, and the patient was admitted and put on azithromycin, lopinavir-ritonavir, and hydroxychloroquine medications (day 0). Obstetric ultrasound examination at admission showed no fetal anomalies, normal Doppler parameters, and a normal

amount of amniotic fluid. The day after admission (day 1), the patient's condition worsened and she was transferred to the intensive care unit (ICU), where she underwent intubation for mechanical ventilation on day 2 (23 1/7 weeks of gestation). Fetal prognosis was estimated to be poor owing to gestational age. After discussion with the mother, expectant management of the pregnancy was decided on by a multidisciplinary team (obstetricians and critical care and infectious disease specialists). Elective delivery was accorded with the patient before intubation if deterioration persisted. Blood tests were performed daily, and pro-inflammatory markers related to COVID-19 severity (IL-6 and D-dimer) were also monitored (Fig. 1).⁹ The result of the SARS-CoV-2 RT-PCR test in peripheral blood was negative.

Fetal well-being scans (Siemens Acuson NX2) were conducted daily by the ICU team to check fetal heart rate and weekly by a fetal medicine specialist to assess fetal growth, Doppler parameters, and the amount of amniotic fluid and to detect any potential abnormalities. Fetal heart rate was always within the normal range, without episodes of tachycardia or bradycardia.

On day 6 (23 5/7 weeks of gestation), fetal skin edema was observed with no ascites, hydrothorax, thickened placenta, or other signs of hydrops fetalis. Edema was generalized, but it was more evident in the scalp and trunk. A detailed survey for anomalies and fetal echocardiography were performed, showing no abnormal results. The same findings persisted on day 10 (24 2/7 weeks), and no structural anomalies were found (Fig. 2). Doppler examinations of the umbilical artery, middle cerebral artery, ductus venosus, and uterine arteries were also within normal limits. Maternal indirect antiglobulin and serologic tests were obtained, being negative for cytomegalovirus, varicella zoster virus, parvovirus B19, *Toxoplasma gondii*, herpes virus, and rubella. An amniocentesis was

Table 1. Patients' Relevant Clinical Findings

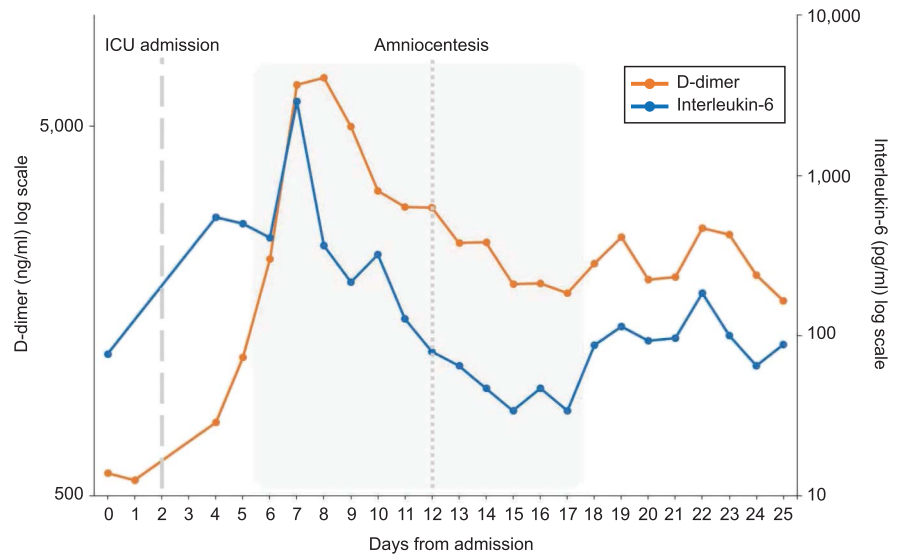
Clinical Characteristics	Patient 1	Patient 2
Age (y)	50	30
Ethnicity	White	Latin American
Nuchal translucency in 1st trimester (mm)	1.28	2.3
Gestational age at COVID-19 diagnosis (wk)	22.6	20.1
Time from symptom onset to fetal edema (d)	13	10
Maternal serum IL-6* level at COVID-19 diagnosis (pg/mL)	76.47	16.22
Maternal serum D-dimer* level at COVID-19 diagnosis (ng/mL)	576	953
Gestational age at fetal edema diagnosis (wk)	23.5	21.2
Maternal serum IL-6 level at fetal edema diagnosis (pg/mL)	409.5	3.59
Maternal serum D-dimer level at fetal edema diagnosis (ng/mL)	2,190	373
Time RT-PCR remained positive for SARS-CoV-2 infection (d)	17	22
Fetal edema duration (d)	11	14
RT-PCR test result for SARS-CoV-2 in maternal serum	Negative	Negative
IL-6 level in amniotic fluid* (pg/mL)	345.18	109.4

COVID-19, coronavirus disease 2019; IL-6, interleukin-6; RT-PCR, reverse-transcription polymerase chain reaction; SARS-CoV-2, severe acute respiratory syndrome coronavirus 2.

* Reference ranges: serum IL-6: 0–4.3 pg/mL; D-dimer: 0–243 ng/mL; IL-6 in amniotic fluid: median values ranging from 150.5 to 339 pg/mL.¹⁰

Fig. 1. Proinflammatory marker evolution during admission in case 1. Fetal skin edema was observed between days 6 and 17 and is delimited by a grey area. Intensive care unit (ICU) admission and amniocentesis were on days 2 and 12, respectively.

Garcia-Manau. Fetal Skin Edema in Pregnant Women With COVID-19. *Obstet Gynecol* 2020.



performed on day 12. The results of the genetic test (Quantitative Genomic Hybridization Array, 8 60K Agilent G4827A CGH (ISCA v2 array) were normal. The RT-PCR test result for SARS-CoV-2 in amniotic fluid was negative, and the IL-6 level in amniotic fluid was within the normal range.¹⁰ Tests in amniotic fluid were negative for cytomegalovirus, varicella zoster virus, parvovirus B19, *T gondii*, and sexually transmitted infectious agents (*Chlamydia trachomatis*, *Neisseria gonorrhoeae*, *Mycoplasma hominis*, *Ureaplasma parvum*, *Mycoplasma genitalium*, *Ureaplasma urealyticum*, and *Trichomonas vaginalis*).

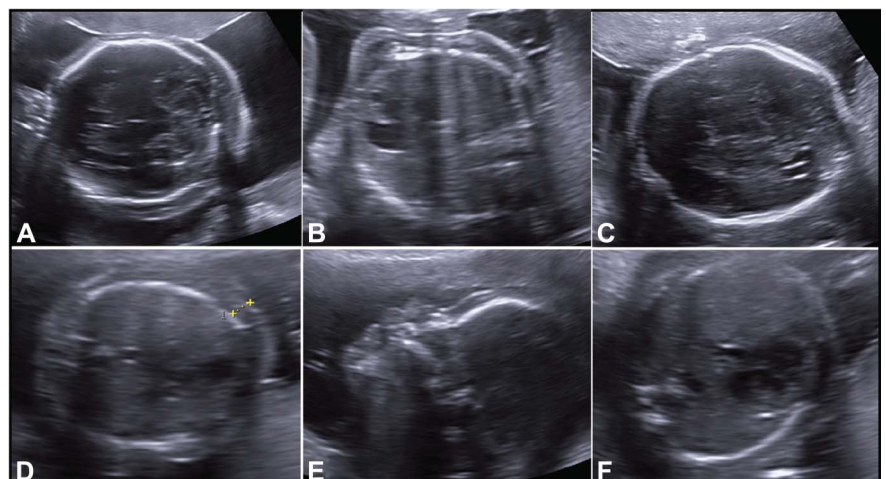
One week later (day 17, 25 2/7 weeks of gestation), the maternal condition improved: PaO₂ progressively increased, and oxygen supplementation requirements lowered. Pro-inflammatory markers decreased, and the result of the SARS-CoV-2 RT-PCR test on oropharyngeal and nasopharyngeal swabs was negative. Simultaneously, the fetal edema had almost disappeared on ultrasound examination (Fig. 2).

CASE 2

A 30-year-old primigravid woman at 20 1/7 weeks of gestation with no relevant medical history presented to the emergency department (day 0) with cough and fever in the previous 48 hours. She was living with her husband and her parents, and all three had tested positive for SARS-CoV-2 infection. Her gestation had had an uneventful course. Physical examination revealed a BMI of 32, blood pressure 130/71 mm Hg, temperature of 37.5°C, respiratory rate 16 breaths per minute, and a hemoglobin saturation of 99% on room air. The results of blood tests performed at admission are shown in Table 1. Chest radiography showed no anomalies, and the patient tested positive for SARS-CoV-2 infection on RT-PCR of oropharyngeal and nasopharyngeal swabs. She was diagnosed with mild COVID-19, and she was discharged with no medication to home isolation. Maternal well-being was assessed daily by phone calls, and no deterioration requiring

Fig. 2. Fetal skin edemas. Fetal ultrasound examinations. Case 1: skin edema in transcerebellar (A) and transthoracic (B) planes and its resolution (C). Case 2: skin edema in transthoracic (D) and midsagittal face (E) planes and its resolution (F).

Garcia-Manau. Fetal Skin Edema in Pregnant Women With COVID-19. *Obstet Gynecol* 2020.



hospital admission was observed. On day 8 (21 2/7 weeks of gestation), an ultrasound examination was performed, detecting an isolated mild fetal skin edema with no other abnormalities (Fig. 2). Fetal echocardiography and Doppler parameters were also within normal limits. Fetal heart rate was within the normal range, and no episodes of tachycardia or bradycardia were recorded. Middle cerebral artery velocity was within the normal range. Maternal indirect antiglobulin and serologic tests were obtained, with negative results. Nasopharyngeal RT-PCR test results remained positive, and RT-PCR test results in peripheral blood were negative. The IL-6 level in maternal serum was within the normal range, and D-dimer levels were slightly elevated (Table 1). An amniocentesis was performed, and the RT-PCR assay of the amniotic fluid was negative for SARS-CoV-2 infection. Results of genetic tests (Quantitative Genomic Hybridization Array) and tests for congenital infections (cytomegalovirus, varicella zoster virus, parvovirus B19, *T gondii*, *Chlamydia trachomatis*, *N gonorrhoeae*, *M hominis*, *U parvum*, *M genitalium*, *U urealyticum*, and *T vaginalis*) in amniotic fluid were negative. The IL-6 level in amniotic fluid was normal.¹⁰ On day 22 (23 2/7 weeks of gestation), fetal edema had disappeared after the SARS-CoV-2 RT-PCR test result was negative.

At the time of submission, both women are still pregnant. Their gestations are being closely followed-up, with a complete resolution of the fetal edema, and no other fetal anomalies have been reported.

DISCUSSION

Two cases of fetal transient skin edema in pregnant women with COVID-19 in their second trimester of pregnancy are described. In case 1, the patient was admitted to the ICU and fetal edema followed a time course parallel to the maternal respiratory condition and the pro-inflammatory markers; the edema disappeared with maternal recovery. Patient 2 remained at home with mild symptoms and did not require hospital admission. Pro-inflammatory markers were lower, and the edema was milder and it also disappeared with maternal improvement. In both cases, viremia and amniotic fluid RT-PCR test results were negative for SARS-CoV-2 infection.

There is still inconclusive evidence of transplacentally acquired fetal infection reported in the literature. A study investigated the expression of SARS-CoV-2 receptors, identified as angiotensin-converting enzyme 2, in human maternal-fetal interface and the main fetal organs. The authors conclude that angiotensin-converting enzyme 2 is widely present in the human placenta and in the main fetal organs.¹¹ Another article describes a second-trimester miscarriage in a woman diagnosed with COVID-19 in which placental and amniotic membranes tested positive for SARS-CoV-2 infection.⁶ In another study, three cases of detection of SARS-CoV-2 RNA in pla-

cental or membrane samples are also described; although none of the neonates tested positive.⁴ Recently, the first two cases of positive RT-PCR test results for SARS-CoV-2 infection in mother, neonate, and placental tissues have been reported.⁵ However, none of these studies demonstrate fetal abnormalities or the presence of the virus in amniotic fluid or in cord blood.

Current protocols recommend, for safety reasons, delaying ultrasound scans while pregnant women are positive for SARS-CoV-2 infection, which may result in lack of observation of transient fetal abnormalities.^{12,13} However, at our center we are scanning pregnant women weekly in the framework of an Institutional Review Board-approved observational study (PR(AMI)181/2020), which includes microbiological sampling and ultrasound examinations in pregnant women with COVID-19. During the pandemic, we performed 31 ultrasound examinations on pregnant women with COVID-19, and fetal skin edema was seen in two cases (6.5%; 95% CI 1.8–20.7%).

Some patients with COVID-19 develop a rapid deterioration related to a cytokine storm syndrome due to a massive, virally driven hyperinflammation.^{14,15} It has been demonstrated that maternal cytokines during pregnancy can lead to a failure in multiple fetal organ systems.¹⁶ The fetal edema described in case 1 appeared when the highest maternal serum IL-6 concentrations were noted and while D-dimer was rapidly increasing. By contrast, its resolution was preceded by a progressive decrease in both serum IL-6 and D-dimer values; the lowest concentrations were noted when the edema had disappeared on day 17, coinciding with a negative SARS-CoV-2 RT-PCR test result (Fig. 1). In case 2, edema was observed with a low pro-inflammatory status, as IL-6 levels were within the normal range. The IL-6 levels in amniotic fluid were normal in both cases. For this reason, we believe that SARS-CoV-2 might have an effect on the fetus, regardless of the pro-inflammatory maternal profile.

Despite the overwhelming amount of data generated since the beginning of the COVID-19 outbreak, many questions about the virus-host interactions remain unanswered. Pregnant women represent a small subgroup of patients with COVID-19, and there is a dearth of data about the potential effects of the virus on the fetus.

This report has several limitations. Firstly, two cases are insufficient to draw out significant conclusions. Fetal edema is a nonspecific finding and often idiopathic. Considering other congenital infections, the

time interval from infection to fetal edema was shorter than expected, and fetal edema is not a common finding in cases of intraamniotic inflammation or chorioamnionitis. We, therefore, cannot state that fetal skin edema was caused by SARS-CoV-2 infection, despite the correlation between the disappearance of the edema and the negative test results for the virus. Secondly, the interpretation of a negative result on RT-PCR test for detection of SARS-CoV-2 infection in amniotic fluid is unknown, and the possibility of the virus testing negative in utero cannot be excluded, because this has been demonstrated for other viruses.^{7,17}

To conclude, we report a fetal complication potentially related to COVID-19 in pregnant women. Given these findings and the lack of reports of COVID-19 in the first and second trimesters, a close follow-up of these pregnancies may help to understand the effect on the fetus.

REFERENCES

- World Health Organization. Coronavirus disease (COVID-19) situation reports. Available at: <https://www.who.int/emergencies/diseases/novel-coronavirus-2019/situation-reports>. Retrieved April 18, 2020.
- Rodó C, Suy A, Sulleiro E, Soriano-Arandes A, Maiz N, García-Ruiz I, et al. Pregnancy outcomes after maternal Zika virus infection in a non-endemic region: prospective cohort study. *Clin Microbiol Infect* 2019;25:633.e5–9.
- Neu N, Duchon J, Zachariah P. TORCH infections. *Clin Perinatol* 2015;42:77–103, viii.
- Penfield CA, Brubaker SG, Limaye MA, Lighter J, Ratner AJ, Thomas KM, et al. Detection of SARS-COV-2 in placental and fetal membrane samples. *Am J Obstet Gynecol MFM* 2020. [Epub ahead of print].
- Patanè L, Morotti D, Giunta MR, Sigismondi C, Piccoli MG, Frigerio L, et al. Vertical transmission of COVID-19: SARS-CoV-2 RNA on the fetal side of the placenta in pregnancies with COVID-19 positive mothers and neonates at birth. *Am J Obstet Gynecol MFM* 2020. [Epub ahead of print].
- Baud D, Greub G, Favre G, Gengler C, Jatón K, Dubruc E, et al. Second-trimester miscarriage in a pregnant woman with SARS-CoV-2 infection. *JAMA* 2020;323:2198–200.
- Yu N, Li W, Kang Q, Zeng W, Feng L, Wu J. No SARS-CoV-2 detected in amniotic fluid in mid-pregnancy. *Lancet Infect Dis* 2020 [Epub ahead of print].
- Lamouroux A, Attie-Bitach T, Martinovic J, Leruez-Ville M, Ville Y. Evidence for and against vertical transmission for severe acute respiratory syndrome coronavirus 2. *Am J Obstet Gynecol* 2020;223:91.e1–4.
- Terpos E, Ntanasis-Stathopoulos I, Elalamy I, Kastritis E, Sergentanis TN, Politou M, et al. Hematological findings and complications of COVID-19. *Am J Hematol* 2020;95:834–7.
- Bamberg C, Fotopoulou C, Linder M, Roehr CC, Dudenhausen JW, Henrich W, et al. Mid-trimester amniotic fluid concentrations of the proinflammatory cytokines IL-6, IL-8, TNF- α , and lipopolysaccharide binding protein in normal pregnancies: a prospective evaluation according to parity, gestational age, and fetal gender. *J Perinat Med* 2011;39:403–9.
- Li M, Chen L, Zhang J, Xiong C, Li X. The SARS-CoV-2 receptor ACE2 expression of maternal-fetal interface and fetal organs by single-cell transcriptome study. *PLoS One* 2020;15:e0230295.
- Abu-Rustum RS, Akolekar R, Sotiriadis A, Salomon LJ, Da Silva Costa F, Wu Q, et al. ISUOG consensus statement on organization of routine and specialist obstetric ultrasound services in context of COVID-19. *Ultrasound Obstet Gynecol* 2020;55:863–70.
- Bourne T, Kyriacou C, Coomarasamy A, Al-Memar M, Leonard M, Kirk E, et al. ISUOG Consensus Statement on rationalization of early-pregnancy care and provision of ultrasonography in context of SARS-CoV-2. *Ultrasound Obstet Gynecol* 2020;55:871–8.
- Mehta P, McAuley DF, Brown M, Sanchez E, Tattersall RS, Manson JJ, et al. COVID-19: consider cytokine storm syndromes and immunosuppression. *Lancet* 2020;395:1033–4.
- Ye Q, Wang B, Mao J. The pathogenesis and treatment of the cytokine storm in COVID-19. *J Infect* 2020;80:607–13.
- Yockey LJ, Iwasaki A. Interferons and proinflammatory cytokines in pregnancy and fetal development. *Immunity* 2018;49:397–412.
- Rodó C, Suy A, Sulleiro E, Soriano-Arandes A, Antón A, García-Ruiz I, et al. In utero negativization of Zika virus in a foetus with serious central nervous system abnormalities. *Clin Microbiol Infect* 2018;24:549.e1–3.

PEER REVIEW HISTORY

Received May 26, 2020. Received in revised form June 11, 2020. Accepted June 23, 2020. Peer reviews and author correspondence are available at <http://links.lww.com/AOG/B990>.